

# What's new in medical management strategies for raised intra-abdominal pressure: evaluating intra-abdominal contents, improving abdominal wall compliance, pharmacotherapy, and continuous negative extra-abdominal pressure

Bart De Keulenaer<sup>1,2</sup>, Adrian Regli<sup>1,3,4</sup>, Inneke De laet<sup>5</sup>, Derek J. Roberts<sup>6</sup>, Manu L.N.G. Malbrain<sup>5</sup>

<sup>1</sup>*Intensive Care Medicine, Fremantle Hospital, Fremantle, Western Australia, Australia*

<sup>2</sup>*School of Surgery, University of Western Australia, Crawley, Western Australia, Australia*

<sup>3</sup>*School of Medicine and Pharmacology, University of Western Australia, Perth, Western Australia, Australia*

<sup>4</sup>*Medical School, University of Notre Dame Australia, Fremantle, Western Australia, Australia*

<sup>5</sup>*Intensive Care Unit, Ziekenhuis Netwerk Antwerpen, ZNA Stuivenberg, Antwerp, Belgium*

<sup>6</sup>*Departments of Community Health Sciences and Surgery, Foothills Medical Centre and the University of Calgary, Calgary, Alberta, Canada*

## Abstract

In the future, medical management may play an increasingly important role in the prevention and management of intra-abdominal hypertension (IAH). A review of different databases was used (PubMed, MEDLINE and EMBASE) with the search terms 'Intra-abdominal Pressure' (IAP), 'IAH', 'Abdominal Compartment Syndrome' (ACS), 'medical management' and 'non-surgical management'. We also reviewed all papers with the search terms 'IAH', 'IAP' and 'ACS' over the last three years, only extracting those papers which showed a novel approach in the non-surgical management of IAH and ACS.

IAH and ACS are associated with increased morbidity and mortality. Non-surgical management is an important treatment option in critically ill patients with raised IAP. There are five medical treatment options to be considered to reduce IAP: 1) improvement of abdominal wall compliance; 2) evacuation of intra-luminal contents; 3) evacuation of abdominal fluid collections; 4) optimisation of fluid administration; and 5) optimisation of systemic and regional perfusion.

This paper will review the first three treatment arms of the WSACS algorithm: abdominal wall compliance; evacuation of intra-luminal contents and evacuation of abdominal fluid collections. Emerging medical treatments will be analysed and finally some alternative specific treatments will be assessed. Other treatment options with regard to optimising fluid administration and systemic and regional perfusion will be described elsewhere, and are beyond the scope of this review.

Medical management of critically ill patients with raised IAP should be instigated early to prevent further organ dysfunction and to avoid progression to ACS. Many treatment options are available and are often part of routine daily management in the ICU (nasogastric, rectal tube, prokinetics, enema, sedation, body position). Some of the newer

Należy cytować wersję z:

*De Keulenaer B, Regli A, De laet I, Roberts DJ, Malbrain MLNG: What's new in medical management strategies for raised intra-abdominal pressure: evacuating intra-abdominal contents, improving abdominal wall compliance, pharmacotherapy, and continuous negative extra-abdominal pressure. Anaesthesiol Intensive Ther 2015; 47: 54–62.*

treatments are very promising options in specific patient populations with raised IAP. Future studies are warranted to confirm some of these findings.

**Key words:** intra-abdominal hypertension, Abdominal Compartment Syndrome, non-surgical management, intra-abdominal pressure, medical management, neuromuscular blockers, gastric evacuation, paracentesis, pharmacotherapy

Anestezjologia Intensywna Terapia 2015, tom XLVII, nr 1, 56–64

Intra-abdominal hypertension (IAH) and abdominal compartment syndrome (ACS) are associated with increased morbidity and mortality among multiple types of patient populations. [1] Although clinical examination alone is an inaccurate predictor of elevated intra-abdominal pressure (IAP), regular measurements of IAP will identify those at risk of developing IAH/ACS [2]. The World Society of the Abdominal Compartment Syndrome (WSACS, [www.wsacs.org](http://www.wsacs.org)) has published definitions and guidelines for the diagnosis and management of patients with IAH and ACS [3, 4]. These guidelines have recently been revised [5]. The WSACS medical management algorithm [6] is based on five treatment options: 1) improvement of abdominal wall compliance; 2) evacuation of intra-luminal contents; 3) evacuation of intra-abdominal space occupying lesions; 4) optimisation of fluid management; and 5) optimisation of systemic and regional perfusion.

This algorithm is based on four important principles. First regular measurements of IAP are necessary to diagnose IAH and ACS. When IAP is increased, medical management should be instigated as soon as possible to reduce IAP and prevent ACS. Further, goal-directed optimisation of systemic perfusion is important to maintain organ function while surgical decompression is necessary when previously mentioned interventions become unsuccessful. Figure 1 shows the WSACS medical management algorithm, which outlines a stepwise approach to non-operative management of IAH and ACS. Although evacuating gastrointestinal intra-luminal contents or intra-abdominal space-occupying lesions or improving abdominal wall compliance have been suggested as possible medical treatments for IAH/ACS, evidence supporting these suggestions has not yet been adequately synthesised. Moreover, while a number of diverse yet novel pharmacological interventions have been suggested for the treatment of IAH/ACS, their role remains undetermined.

This article therefore attempts to examine whether the above medical or minimally invasive interventions may improve IAP or patient-important outcomes among those with IAH/ACS. Other medical treatment options to improve IAH/ACS, including optimisation of fluid admin-

istration and systemic/regional perfusion, are discussed elsewhere.

## METHODS

We searched PubMed, MEDLINE and EMBASE, using the search terms 'Intra-abdominal Pressure' (IAP), 'IAH', 'ACS', 'medical management' and 'non-surgical management.' We also reviewed all papers with the search terms 'IAH', 'IAP' and 'ACS' over the last three years, only extracting those papers which showed a novel approach to non-surgical management of IAH and ACS.

## EVACUATION OF INTRA-LUMINAL CONTENTS

Insertion of nasogastric and/or rectal tubes or use of prokinetic agents, enemas, or colonic decompression may reduce GI intra-luminal, and therefore intra-abdominal, volume and lead to reductions in IAP among selected populations of patients. However, the evidence supporting reductions in IAP with these interventions is limited, and no study has yet reported improved patient outcomes.

## INSERTION OF NASOGASTRIC AND/OR RECTAL TUBES

Peces et al. [7] described a case report of massive gastric dilatation and anuria which resolved after naso-gastric tube decompression. De Keulenaer et al. [8] demonstrated that insertion of a nasogastric tube in a patient with acute ACS and cardiac arrest immediately reduced the IAP from 23 mm Hg to 7 mm Hg and promoted the return of spontaneous circulation. A similar observation was made by Mahajna et al. [9] where insertion of a naso-gastric tube immediately resolved the ACS by reducing the IAP from 31 mm Hg to normal values. In a case of large bowel obstruction by gas or fluid, management of the colonic obstruction using a rectal tube has been shown to be effective and safe and should be attempted first before surgical intervention is considered [10]. Overall, although both nasogastric and rectal tube drainage may be effective ways to reduce IAP, are easy to insert and relatively safe, studies confirming their effectiveness and impact on patient-important outcomes are needed. Absolute and relative contra-indications for their use should always be considered (e.g. oesophageal varices).

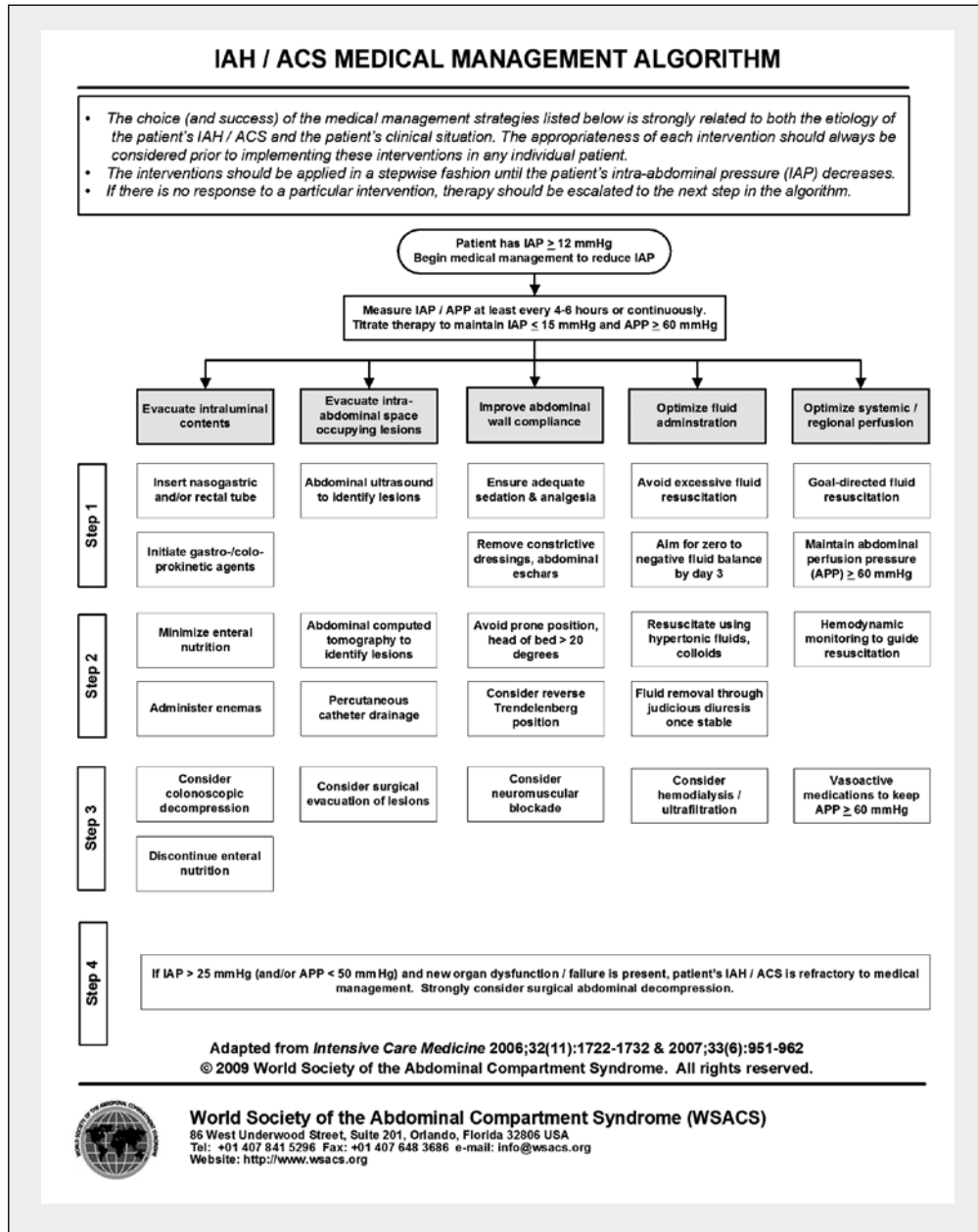


Figure 1. IAH and ACS medical management algorithm

### PROKINETICS

Shaikh et al. [11] described a 36-year-old male with pseudomembranous colitis due to *clostridium difficile* infection causing ACS with acute kidney injury. After excluding obstruction via computed tomography of the abdomen, neostigmine was given which reduced the IAP from 30 mm Hg to 14 mm Hg when the patient started to pass stools again. Other prokinetics such as metoclopramide and erythromycin are widely used to treat abdominal distension and ileus (see also the specific treatments mentioned in 'Chinese Medicine' below). The WSACS recommends its

use in patients with raised IAP but little data is available in the literature.

### ENEMA AND COLONIC DECOMPRESSION

Postoperative ileus and toxic megacolon need timely recognition and close monitoring (including serial IAP measurements) as perforation, ischaemia and peritonitis necessitate urgent surgical intervention and are associated with a high mortality. Non-operative management is the initial treatment option of choice. Prokinetics, neostigmine and enemas have all been used successfully to manage

postoperative ileus. However, in patients not responding to maximal supportive and pharmacologic therapy, endoscopic decompression should be considered [12].

## EVACUATION OF INTRA-ABDOMINAL SPACE OCCUPYING LESIONS

Intra-abdominal fluid collections such as ascites or blood can cause or contribute to IAH and/or ACS. In the acute setting of primary ACS, secondary to trauma, urgent surgical intervention is often needed to control bleeding and reduce IAP.

However, more commonly seen in intensive care units (ICU) is massive fluid resuscitation and capillary leak causing IAH and secondary ACS. Apart from medical management to control IAP, percutaneous catheter decompression (PCD) may be an effective alternative to treat elevated IAP in this group of patients. Cheatham et al. [13] showed in 62 patients with IAH/ACS treated with PCD versus traditional open abdominal decompression (OAD) that both techniques were equally effective. Successful PCD therapy was associated with either fluid drainage above 1,000 mL or a decrease in IAP of > 9 mm Hg in the first four hours post decompression. PCD appears to be most effective in patients with secondary ACS due to pancreatitis, liver cirrhosis, sepsis, and massive fluid resuscitation and in burns. Latenser et al. [14] showed that PCD reduced IAP and prevented ACS in 55% of burned patients. PCD is a relatively simple technique, cost effective and less invasive than OAD. Bedside ultrasonography to identify intraperitoneal fluid or blood is necessary. Despite the above benefits, randomised trials are necessary to confirm that PCD is safe and efficacious for improving clinical outcomes in those with IAH and ACS compared to standard therapy or surgical decompression of the abdomen.

## IMPROVEMENT OF ABDOMINAL WALL COMPLIANCE

### NEUROMUSCULAR BLOCKING AGENTS

Neuromuscular blocking agents (NMB) have been used as rescue therapy to reduce IAP. De laet et al. [15] reported

an immediate reduction in IAP from 18 mm Hg to 14 mm Hg within 30 minutes of a single bolus of cisatracurium in a small prospective study of ten patients. Deeren et al. [16] demonstrated in four patients with non-traumatic brain injury a significant drop in IAP from 17.4 mm Hg to 9.2 mm Hg after a single bolus of NMB. Similar findings have been observed by others [17–19], and are summarised in Table 1. Routine administration of NMB in the ICU cannot be recommended due to the increased risk of ventilator-associated pneumonia, muscle weakness, thromboembolic complications and atelectasis. However, a single bolus of NMB can be tried in patients with IAH and/or ACS who are waiting for surgical decompression or as an adjuvant or rescue therapy along with other non-surgical interventions.

### SEDATION AND ANALGESIA

The WSACS recommends that IAP should be expressed in mm Hg and measured at end-expiration in the complete supine position after ensuring that abdominal muscle contractions are absent and with the transducer zeroed at the level of the mid-axillary line [1]. Only a few studies have investigated the effects of sedation and analgesia on IAP. Pain or inflammation can stimulate the anterolateral abdominal muscles and the muscles of the trunk. As a result, the muscles pull on the rib margins in both a downward and inward direction, reducing the ribcage volume, pressing on the abdominal contents, and instantly increasing IAP.

Therefore, sedation and/or analgesia have the potential to reduce IAP. Tasdogan et al. [21] studied the effects of propofol versus dexmedetomidine infusion in 40 patients with severe sepsis post abdominal surgery. In the dexmedetomidine group, the IAP dropped after 24 h from  $18.7 \pm 3.9$  mm Hg to  $12.4 \pm 5.8$  mm Hg. This was in large contrast to a much smaller reduction in IAP in the propofol group (from  $18.9 \pm 5.2$  mm Hg to  $18.1 \pm 2.8$  mm Hg). Hako-byan et al. [22] compared the effects of epidural analgesia versus an opioid infusion. In the epidural group, the IAP decreased from  $16.8 \pm 4.7$  mm Hg to  $6.3 \pm 3.1$  mm Hg, whereas no decrease in IAP was seen in the intravenous

**Table 1.** Effect of neuromuscular blocking (NMB) agents on intra-abdominal pressure (IAP) measurements

Reference	N	Year	IAP baseline (mm Hg)	IAP post NMB (mm Hg)	Delta IAP (mm Hg)
Chiles [19]	1	2011	40	17	23
De laet [15]	10	2007	18	14	4
Kimball [20]	10	2005	NA	NA	9.2
Deeren [16]	4	2005	17.4	9.2	8.2
De Waele [18]	1	2003	26	14	12
Macalino [17]	1	2002	27.2	17.6	9.6

N — observations; NA — not available; NMB — neuromuscular blocking agent; delta IAP — IAP at baseline minus IAP post NMB

**Table 2.** Effect of body positioning on intra-abdominal pressure measurements

Reference	N (n)	Supine	HOB 15	HOB 30	HOB 45	Lateral	Reverse Trendelenburg	Prone
Malbrain* [28]	37 (79)	8.8 ± 3.9	NA	NA	17.1 ± 6.1	NA	13.3 ± 4.8	
Chionh** [29]	58 (174)	7 (0.7–13.2)	NA	8.5 (2.2–14)	10.3 (2.9–16.2)	NA	NA	
McBeth* [30]	37 (300)	13.4 ± 4.2	NA	18.4 ± 4.8	21.5 ± 5.0	NA	NA	
Vasquez*** [31]	45 (675)	10.2 (8.7–11.8)	12.4 (10.7–14.1)	14.0 (12.3–15.8)	16.7 (14.8–18.5)	NA	19.3 (16.8–21.8)	
Cheatham# [25]	132 (396)	11.8 (11.4–12.2)	13.3 (12.8–13.8)	15.4 (14.9–15.9)	NA	NA	NA	
De Keulenaer* [32]	10 (60)	6.6 ± 2.9	NA	NA	NA	11.2 ± 3.3	NA	
Cobb* [33]	20 (180)	1.8 ± 2.0	NA	NA	16.7	NA	NA	
Chiumello* [34]	11 (60)	8.8 ± 2.1	NA	NA	NA	NA	NA	10.7 ± 2.5
Hering* [35]	12 (24)	10 ± 3	NA	NA	NA	NA	NA	13 ± 4
Ejike* [36]	77 (580)	8.4 ± 4.0	NA	10.6 ± 4.0	NA	NA	NA	
Yi* [26]	88 (5280)	9.8 ± 3.6	NA	14 ± 3.6	17 ± 3.9	NA	NA	

N — observations; (n): number of measurements between brackets; HOB — head of bed elevation; \*data is expressed as mean ± SD; \*\*data expressed as median with range; \*\*\*data expressed as mean with 95% CI; #data expressed as mean with range

opioid group. Some have suggested that opioids could stimulate active phasic expiratory activity, subsequently increasing IAP [23]. However, a recent study in animals did not find such a correlation [24].

### BODY POSITIONING

Studies have shown that IAP in the semi-recumbent position increases in relation to head of bed elevation (HOB). Cheatham et al. [25] demonstrated in a multicentre trial of 132 ventilated patients that IAP increased by 1.5 and 3.6 mm Hg when patients were placed in the semi-recumbent position at 15° and 30° HOB respectively. However, these differences were less obvious in patients with IAP > 20 mm Hg. A more recent study by Yi et al. [26] showed an increase in IAP by 4.1 mm Hg among 88 patients in the semi-recumbent position at 30° HOB. Pressure differences between the supine and HOB at 30° in other trials (Table 2) ranged between 0.41 and 5 mm Hg, with a higher range at HOB 45° (2.7–14.9 mm Hg). In children, Ejike et al. [27] found a 2.2 mm Hg pressure increase at 30° HOB. Table 2 outlines all studies looking at body positioning and the effects on IAP. Whether these differences constitute a true pressure increase, or just an external pressure effect of the abdominal contents exerting pressure on the bladder, remains a subject for debate. However, De Keulenaer [8] described a patient on non-invasive positive pressure ventilation who developed cardiac arrest shortly after being put in the upright position and hypothesised that increased IAP may have been a factor in this occurrence.

Although no clear recommendations can be stated, clinicians should be aware of this pressure increase when changing body position, especially in patients with impending ACS, although other factors like body anthropomorphy may also play a role [37].

### NEW MEDICAL TREATMENT OPTIONS TISSUE PLASMINOGEN ACTIVATOR (TPA)

The use of tPA, a fibrinolytic agent, to evacuate a retroperitoneal haematoma post endovascular aneurysm repair of a ruptured abdominal aortic aneurysm was studied by Horer et al. [38]. A decompression technique was used in which tPA was delivered to the haematoma via a catheter inserted into the retroperitoneum under CT guidance. After exclusion of a type 1 endoleak via angiogram, 13 patients who developed ACS with multiple organ failure in the ICU were included in the study. The mean IAP before decompression was 23.5 mm Hg (range 12–35), which dropped to a mean of 16 mm Hg (range 10–28.5) after 24 hours when tPA was used. Drainage of haematoma increased from 370 mL (range 5–1,000) before tPA to 1,520 mL (range 170–2,900) after. This coincided with improved urinary output and haemodynamics. Only one patient did not respond and proceeded to decompressive laparotomy.

Although these results were not compared to a control group receiving drainage without tPA, tPA-assisted decompression seems to be a simple and minimally invasive technique that can be done under local anaesthesia and has the potential to evacuate large amounts of haematoma, thereby effectively reducing IAP. However, studies confirming the safety and effectiveness of this intervention in vascular surgical patients are required before it can be recommended.

### THEOPHYLLINE INFUSION

Bodnar et al. [39] found a positive correlation between IAH and increased levels of serum adenosine and interleukin 10 concentrations in 45 surgical patients with IAP > 12 mm Hg. Based on these findings, the authors conducted a study comparing standard medical treatment in patients with IAH (implementing the WSACS algorithm) versus standard medi-

cal treatment and theophylline infusions twice daily. Patients who developed IAP > 20 mm Hg and one organ failure proceeded to surgical decompression. They found that in the theophylline group the mean IAP decreased from 18.2 mm Hg to 9.5 mm Hg and that adenosine levels dropped from 1.1  $\mu$ M to 0.04  $\mu$ M. Both groups were matched in terms of age, sex, severity scores and co-morbidity. Mortality in the theophylline group was 0% versus 55% in the standard group. Adenosine influences vascular tone, renal function and cardiac contractility (negative inotropic and chronotropic effect). The use of theophylline by counteracting adenosine binding to adenosine receptors has been shown to improve renal function, splanchnic perfusion, and cardiac contractility. The authors concluded that theophylline infusions improved IAH-related mortality in surgical patients by possibly reducing circulating adenosine concentrations [40]. Future studies are warranted to confirm these findings. The same authors also found increased serum adenosine and interleukin 10 levels to be new laboratory markers of increased intra-abdominal pressure [39].

### **OCTREOTIDE**

Oxidative tissue damage as assessed by increased myeloperoxidase (MPO) activity, lipid peroxidation, and decreased levels of glutathione levels in intestinal and hepatic tissue plays an important role in progression from IAH to ACS. However, reperfusion of decompressed tissue induces a more prominent injury compared to ischaemia itself [41]. Reperfusion promotes generation of various reactive oxygen metabolites via activated neutrophils that cause increased microvascular permeability, interstitial oedema, impaired vasoregulation, inflammatory cell infiltration, and parenchymal cell dysfunction and necrosis.

Octreotide, a synthetic somatostatin analogue, has been shown to improve the reperfusion-induced oxidative damage in rats with ACS by reducing levels of MPO activity and malondialdehyde and increasing levels of glutathione when given before decompression. Therefore, octreotide might ultimately be shown to have a therapeutic role as a reperfusion injury-limiting agent among patients with IAH and ACS [42, 43].

### **MELATONIN**

Studies have shown that melatonin has free radical scavenging properties and the ability to inhibit lipid peroxidation [43, 44]. Others have demonstrated melatonin's anti-inflammatory effects by inhibiting activation of neutrophils, their influence on haematopoiesis (by stimulating the immune response), and their stimulation of anti-oxidant enzymes [43, 45, 46]. Sener et al. [47] investigated if melatonin could reverse the oxidative tissue damage induced by ACS in rats. They found that reperfusion of decompressed

tissue was associated with decreased levels of glutathione, increased malondialdehyde (MDA) levels (an indicator of lipid peroxidation), and MPO activity. Those levels were reversed when melatonin was given prior to decompression, confirming its protective effect on oxidative stress.

### **CONTINUOUS NEGATIVE EXTRA-ABDOMINAL PRESSURE (CNAP)**

Bloomfield et al. [48] showed a significant reduction in IAP when continuous negative pressure via a large poncho connected to a vacuum into which the entire animal was placed was applied. The mean IAP decreased from  $30.7 \pm 1.3$  to  $18.2 \pm 1.3$  mm Hg. They also found reduced central venous, inferior vena cava, and intracranial pressures when CNAP was applied as well as pulmonary artery occlusion pressure and peak inspiratory pressure, albeit not statistically significant. Sugerma et al. [49] showed that headaches and pulsatile tinnitus in patients with pseudotumor cerebri (PTC) disappeared when IAP was reduced by CNAP. Seven patients with PTC were free of symptoms shortly after CNAP was applied, with a reduction of IAP from  $19.1 \pm 3$  to  $12.5 \pm 2.8$  cm H<sub>2</sub>O. Intra-pleural, central venous, jugular venous and cerebral vascular pressures were also reduced. The downside of this device however was that when activated the shell was pulling into the patient causing discomfort in the lower chest and pelvic areas. This was anticipated by using a counter-traction device. Nevertheless, most patients tolerated the treatment with significant relief of symptoms. Valenza et al. [50] investigated in 30 patients if CNAP could decrease IAP. Following measurements of IAP at baseline, CNAP was applied at pressure equal to IAP (CNAP<sub>0</sub>), 5 cm H<sub>2</sub>O or 10 cm H<sub>2</sub>O more negative than CNAP<sub>0</sub>. IAP was reduced from  $8.7 \pm 4.3$  to  $6 \pm 4.2$  mm Hg (basal versus CNAP<sub>0</sub>), to  $4.3 \pm 3.2$  mm Hg (CNAP<sub>0</sub> vs CNAP<sub>-5</sub>) and  $3.8 \pm 3.7$  mm Hg (CNAP<sub>0</sub> vs CNAP<sub>-10</sub>). So the more negative pressure was applied, the more IAP was reduced. They also found a significant reduction of central venous pressure with increasing CNAP, probably related to a blood shift from the intra-thoracic to the abdominal compartment. The limitations of this trial were the relatively small sample size, the exclusion of haemodynamically unstable and abdominal surgical patients, and the fact that many patients had normal IAP. In a further trial, they studied the effect of CNAP on respiratory system compliance, central venous pressure and IAP in patients with or without IAH [51]. CNAP reduced pleural pressures, resulted in higher transpulmonary pressures and thus better lung volumes and increased chest wall elastance. Interestingly, CNAP improved chest wall elastance during IAH perhaps by pulling the diaphragm downwards.

In conclusion, all these studies have shown that CNAP applied to the abdomen reduces IAP with minimal effects on mean arterial pressure and cardiac output. Respiratory

mechanics improve especially in patients with IAH. It is simple and easy to apply with minimal discomfort to the patient. Studies of surgical decompression have shown it to be associated with a mortality rate of 42 to 62.5% [52, 53]. Therefore, a non-invasive, non-surgical intervention like CNAP may be beneficial. However, many questions remain unanswered: how long (intermittent, continuous, how many times a day) should CNAP be applied as transient skin lesion in humans? What patient population should be targeted, as no data is available in patients with haemodynamic compromise, patients with abdominal surgery (where the stretch of the abdominal wall may enhance dehiscence or disruption), or patients presenting with ACS where intervention is an emergency?

### VITAMIN C

Free radicals have emerged as important mediators for burn injury at the cellular level. Continuous high dose ascorbic acid (Vitamin C) infusion ( $66 \text{ mg kg}^{-1} \text{ h}^{-1}$ ) appears to be a useful adjunct in minimising the effects of free radical injury since it attenuates postburn lipid peroxidation and reduces fluid resuscitation requirements and oedema generation in severely burned patients [54]. Adjuvant administration of high-dose ascorbic acid during the first 24 hours after thermal injury significantly reduces resuscitation fluid volume requirements, body weight gain, and wound oedema. A reduction in the severity of respiratory dysfunction was also apparent in these patients. Therefore (by limitation of fluid intake and capillary leak), high dose vitamin C carries the potential to prevent secondary IAH and ACS in severely burned patients [55–57].

### DA CHENG QI DECOCTION AND GLAUBER'S SALT, TRADITIONAL CHINESE MEDICINE

Zhang et al. [58] investigated the effect of traditional Chinese medicines Da Cheng Qi Decoction [59, 60] and Glauber's salt [61] in combination with the standard treatment measures of severe acute pancreatitis (SAP). Standard treatment included parenteral nutrition, gastrointestinal decompression, continuous peripancreatic vascular pharmaceutical infusion, drug therapy and supportive measures. Eighty patients with SAP were divided into two groups. Group one received Da Cheng Qi Decoction enema (100 mL) and Glauber's salt once a day for seven days, group two (control) 100 ml normal saline enema for seven days. IAP was measured for seven days. They found that on days 4 and 5, IAP in the study group was significantly reduced compared to the control group ( $8.2 \pm 1.5$  vs  $15.2 \pm 3.7$  mm Hg day 4 and  $8.7 \pm 3.2$  vs  $14.7 \pm 2.9$  day 5). They also found an improved mortality rate of 7.5% in the study group versus 20% in the control group, shorter hospital stay, reduced cyst formation rate, and better symptom relief.

Da Cheng Qi Decoction is a traditional Chinese medicine that works as a prokinetic but unfortunately little data is available in Western literature. Glauber's salt is used as an anti-tissue oedema agent, but again very limited data is available. The above findings are interesting and their effects might be explained by improvement of the abdominal wall compliance via negative fluid balance (Glauber's salt) and evacuation of intraluminal contents via gastroprokinetics (Da Chang Qi Decoction).

### CONCLUSIONS

Medical management of critically ill patients with raised IAP should be instigated early to prevent further organ dysfunction and to avoid progression to ACS. Many treatment options are available and are often part of routine daily management in the ICU (nasogastric, rectal tube, prokinetics, enema, sedation, body position). Some of the newer treatments such as tPA-assisted decompression of a haematoma, theophylline infusions to reduce circulating adenosine concentrations, octreotide as a reperfusion injury-limiting agent, and CNAP to reduce IAP, are all very promising treatment options in specific patient populations (ruptured triple A, pancreatitis) with raised IAP. Future studies are warranted to confirm some of these findings.

### ACKNOWLEDGEMENTS

All authors are members of the World Society of the Abdominal Compartment Syndrome (<https://www.wsacs.org/>).

Dr Roberts is supported by an Alberta Innovates – Health Solutions Clinician Fellowship Award, a Knowledge Translation Canada Strategic Training in Health Research Fellowship, and funding from the Canadian Institutes of Health Research.

Dr Bart De Keulenaer is the chairman of the CTWG.

Dr Manu Malbrain is founding President of WSACS and current Treasurer. He is a member of the medical advisory Board of Pulsion Medical System and consults for ConvaTec, Kinetic Concepts International and Holtech Medical.

Drs Adrian Regli, Inneke De laet (WSACS Secretary), and Derek J. Roberts have no other conflicts of interest to declare.

Parts of this review contributed to the Proceedings of the 6th World Congress on Abdominal Compartment Syndrome (WCACS, [www.wcacs.org](http://www.wcacs.org)) in Cartagena, Colombia (22–25 May 2013) and were presented at the meeting.

### References:

1. Cheatham ML, Malbrain ML, Kirkpatrick A et al.: Results from the International Conference of Experts on Intra-abdominal Hypertension and Abdominal Compartment Syndrome. II. Recommendations. *Intensive Care Med* 2007; 33: 951–962.
2. Sugrue M, Bauman A, Jones F et al.: Clinical examination is an inaccurate predictor of intraabdominal pressure. *World J Surg* 2002; 26:1428–1431.
3. Malbrain ML, Cheatham ML, Kirkpatrick A et al.: Results from the International Conference of Experts on Intra-abdominal Hypertension and

- Abdominal Compartment Syndrome. I. Definitions. *Intensive Care Med* 2006; 32:1722–1732.
4. Cheatham ML, Malbrain ML et al.: Results from the International Conference of Experts on Intra-abdominal Hypertension and Abdominal Compartment Syndrome. II. Recommendations. *Intensive Care Med* 2007; 33: 951–962.
  5. Kirkpatrick AW, Roberts DJ, De Waele J et al.: Intra-abdominal hypertension and the abdominal compartment syndrome: updated consensus definitions and clinical practice guidelines from the World Society of the Abdominal Compartment Syndrome. *Intensive Care Med* 2013; 39: 1190–1206.
  6. De Keulenaer BL, De Waele JJ, Malbrain ML: Nonoperative management of intra-abdominal hypertension and abdominal compartment syndrome: evolving concepts. *Am Surg* 2011; 77 (Suppl 1): S34–41.
  7. Peces R, Vega C, Peces C, Trebol J, Gonzalez JA: Massive gastric dilatation and anuria resolved with naso-gastric tube decompression. *Int Urol Nephrol* 2010; 42: 831–834.
  8. De Keulenaer BL, De Backer A, Schepens DR, Daelemans R, Wilmer A, Malbrain ML: Abdominal compartment syndrome related to noninvasive ventilation. *Intensive Care Med* 2003; 29: 1177–1181.
  9. Mahajna A, Mitkal S, Krausz MM: Postoperative gastric dilatation causing abdominal compartment syndrome. *World J Emerg Surg* 2008; 3: 7.
  10. Xu M, Zhong Y, Yao L, Xu J, Zhou P, Wang P, Wang H: Endoscopic decompression using a transanal drainage tube for acute obstruction of the rectum and left colon as a bridge to curative surgery. *Colorectal Dis* 2009; 11: 405–409.
  11. Shaikh N, Kettern MA, Hanssens Y, Elshafie SS, Louon A: A rare and unsuspected complication of Clostridium difficile infection. *Intensive Care Med* 2008; 34: 963–966.
  12. Jain A, Vargas HD: Advances and challenges in the management of acute colonic pseudo-obstruction (ogilvie syndrome). *Clin Colon Rectal Surg* 2012; 25: 37–45.
  13. Cheatham ML, Safcsak K: Percutaneous catheter decompression in the treatment of elevated intraabdominal pressure. *Chest* 2011; 140: 1428–1435.
  14. Latenser BA, Kowal-Vern A, Kimball D, Chakrin A, Dujovny N: A pilot study comparing percutaneous decompression with decompressive laparotomy for acute abdominal compartment syndrome in thermal injury. *J Burn Care Rehabil* 2002; 23: 190–195.
  15. De laet I, Hoste E, Verhoben E et al.: The effect of neuromuscular blockers in patients with intra-abdominal hypertension. *Intensive Care Med* 2007; 33: 1811–1814.
  16. Deeren DH, Dits H, Malbrain ML, Deeren DH, Dits H, Malbrain MLNG: Correlation between intra-abdominal and intracranial pressure in nontraumatic brain injury. *Intensive Care Med* 2005; 31: 1577–1581.
  17. Macalino JU, Goldman RK, Mayberry JC, Macalino JU, Goldman RK, Mayberry JC: Medical management of abdominal compartment syndrome: case report and a caution. *Asian J* 2002; 25: 244–246.
  18. De Waele JJ, Benoit D, Hoste E et al.: A role for muscle relaxation in patients with abdominal compartment syndrome? *Intensive Care Med* 2003; 29: 332.
  19. Chiles KT, Feeney CM: Abdominal compartment syndrome successfully treated with neuromuscular blockade. *Indian J Anaesth* 2011; 55: 384–387.
  20. Kimball EJ, Mone M: Influence of neuromuscular blockade on intra-abdominal pressure. *Crit Care Med* 2005; 33 (Suppl. 1): A38.
  21. Tasdogan M, Memis D, Sut N, Yuksel M: Results of a pilot study on the effects of propofol and dexmedetomidine on inflammatory responses and intraabdominal pressure in severe sepsis. *J Clin Anesth* 2009; 21: 394–400.
  22. Hakobyan RV, Mkhoyan GG: Epidural analgesia decreases intraabdominal pressure in postoperative patients with primary intra-abdominal hypertension. *Acta Clin Belg* 2008; 63: 86–92.
  23. Drummond GB, Duncan MK: Abdominal pressure during laparoscopy: effects of fentanyl. *Br J Anaesth* 2002; 88: 384–388.
  24. Dorfelt R, Ambrisko TD, Moens Y: Influence of fentanyl on intra-abdominal pressure during laparoscopy in dogs. *Vet Anaesth Analg* 2012; 39: 390–397.
  25. Cheatham ML, De Waele JJ, De Laet I et al.: The impact of body position on intra-abdominal pressure measurement: a multicenter analysis. *Crit Care Med* 2009; 37: 2187–2190.
  26. Yi M, Leng Y, Bai Y, Yao G, Zhu X: The evaluation of the effect of body positioning on intra-abdominal pressure measurement and the effect of intra-abdominal pressure at different body positioning on organ function and prognosis in critically ill patients. *J Crit Care* 2012; 27: 222.e221–226.
  27. Brismar B, Hedenstierna G, Lundquist H, Strandberg A, Svensson L, Tokics L: Pulmonary densities during anesthesia with muscular relaxation — a proposal of atelectasis. *Anesthesiology* 1985; 62: 422–428.
  28. Malbrain ML: Abdominal pressure in the critically ill: measurement and clinical relevance. *Intensive Care Med* 1999; 25: 1453–1458.
  29. Chionh JJ, Wei BP, Martin JA, Opdam HI: Determining normal values for intra-abdominal pressure. *ANZ J Surg* 2006; 76: 1106–1109.
  30. McBeth PBZD, Widder S, Cheatham M, Zengerink I, Glowka J, Kirkpatrick AW: Effect of patient positioning on intraabdominal pressure monitoring. *Am J Surg* 2007; 193: 644–647.
  31. Vasquez DG, Berg-Copas GM, Wetta-Hall R, Vasquez DG, Berg-Copas GM, Wetta-Hall R: Influence of semi-recumbent position on intra-abdominal pressure as measured by bladder pressure. *J Surg Res* 2007; 139: 280–285.
  32. De Keulenaer BL, Cheatham ML, De Waele JJ et al.: Intra-abdominal pressure measurements in lateral decubitus versus supine position. *Acta Clin Belg* 2009; 64: 210–215.
  33. Cobb WS, Burns JM, Kercher KW, Matthews BD, Norton HJ, Heniford BT: Normal intraabdominal pressure in healthy adults. *J Surg Res* 2005; 129: 231–235.
  34. Chiumello D, Cressoni M, Racagni M et al.: Effects of thoraco-pelvic supports during prone position in patients with acute lung injury/acute respiratory distress syndrome: a physiological study. *Crit Care* 2006; 10: R87.
  35. Hering R, Vorwerk R, Wrigge H et al.: Prone positioning, systemic hemodynamics, hepatic indocyanine green kinetics, and gastric intramucosal energy balance in patients with acute lung injury. *Intensive Care Med* 2002; 28: 53–58.
  36. Ejlke JC, Kadry J, Bahjri K, Mathur M: Semi-recumbent position and body mass percentiles: effects on intra-abdominal pressure measurements in critically ill children. *Intensive Care Med* 2010; 36: 329–335.
  37. Malbrain ML, De laet I: Do we need to know body anthropomorphic data whilst measuring abdominal pressure? *Intensive Care Med* 2010; 36: 180–182.
  38. Horer T, Skoog P, Pirouzram A, Larzon T: Tissue plasminogen activator-assisted hematoma evacuation to relieve abdominal compartment syndrome after endovascular repair of ruptured abdominal aortic aneurysm. *J Endovasc Ther* 2012; 19: 144–148.
  39. Bodnar Z, Keresztes T, Kovacs I, Hajdu Z, Boissonneault GA, Sipka S: Increased serum adenosine and interleukin 10 levels as new laboratory markers of increased intra-abdominal pressure. *Langenbecks Arch Surg* 2010; 395: 969–972.
  40. Bodnar Z, Szentkereszty Z, Hajdu Z, Boissonneault GA, Sipka S: Beneficial effects of theophylline infusions in surgical patients with intra-abdominal hypertension. *Langenbecks Arch Surg* 2011; 396: 793–800.
  41. Kacmaz A, Polat A, User Y, Tilki M, Ozkan S, Sener G: Octreotide improves reperfusion-induced oxidative injury in acute abdominal hypertension in rats. *J Gastrointest Surg* 2004; 8: 113–119.
  42. Kacmaz A, Polat A, User Y, Tilki M, Ozkan S, Sener G: Octreotide: a new approach to the management of acute abdominal hypertension. *Peptides* 2003; 24: 1381–1386.
  43. Reiter RJ, Tan DX, Osuna C, Gitto E: Actions of melatonin in the reduction of oxidative stress. A review. *J Biomed Sci* 2000; 7: 444–458.
  44. Reiter RJ, Tan DX, Poeggeler B, Menendez-Pelaez A, Chen LD, Saarela S: Melatonin as a free radical scavenger: implications for aging and age-related diseases. *Ann N Y Acad Sci* 1994; 719: 1–12.
  45. Cuzzocrea S, Reiter RJ: Pharmacological action of melatonin in shock, inflammation and ischemia/reperfusion injury. *Eur J Pharmacol* 2001; 426: 1–10.
  46. Reiter RJ, Calvo JR, Karbownik M, Qi W, Tan DX: Melatonin and its relation to the immune system and inflammation. *Ann N Y Acad Sci* 2000; 917: 376–386.
  47. Sener G, Kacmaz A, User Y, Ozkan S, Tilki M, Yegen BC: Melatonin ameliorates oxidative organ damage induced by acute intra-abdominal compartment syndrome in rats. *J Pineal Res* 2003; 35: 163–168.
  48. Bloomfield G, Saggi B, Blocher C, Sugeran H: Physiologic effects of externally applied continuous negative abdominal pressure for intra-abdominal hypertension. *J Trauma* 1999; 46: 1009–1014.
  49. Sugeran HJ, Felton IW, 3<sup>rd</sup>, Sismanis A et al.: Continuous negative abdominal pressure device to treat pseudotumor cerebri. *Int J Obes Relat Metab Disord* 2001; 25: 486–490.



50. Valenza F, Bottino N, Canavesi K et al.: Intra-abdominal pressure may be decreased non-invasively by continuous negative extra-abdominal pressure (NEXAP). *Intensive Care Med* 2003; 29: 2063–2067.
51. Valenza F, Irace M, Guglielmi M et al.: Effects of continuous negative extra-abdominal pressure on cardiorespiratory function during abdominal hypertension: an experimental study. *Intensive Care Med* 2005; 31: 105–111.
52. Morris JA, Jr., Eddy VA, Blinman TA, Rutherford EJ, Sharp KW: The staged celiotomy for trauma. Issues in unpacking and reconstruction. *Ann Surg* 1993; 217: 576–584.
53. Schein M, Wittmann DH, Aprahamian CC, Condon RE: The abdominal compartment syndrome: the physiological and clinical consequences of elevated intra-abdominal pressure [see comment]. *J Am Coll Surg* 1995; 180: 745–753.
54. Tanaka H, Matsuda T, Miyagantani Y, Yukioka T, Matsuda H, Shimazaki S: Reduction of resuscitation fluid volumes in severely burned patients using ascorbic acid administration: a randomized, prospective study. *Arch Surg* 2000; 135: 326–331.
55. Kremer T, Harenberg P, Hernekamp F et al.: High-dose vitamin C treatment reduces capillary leakage after burn plasma transfer in rats. *J Burn Care Res* 2010; 31: 470–479.
56. Matsuda T, Tanaka H, Williams S, Hanumadass M, Abcarian H, Reyes H: Reduced fluid volume requirement for resuscitation of third-degree burns with high-dose vitamin C. *J Burn Care Rehabil* 1991; 12: 525–532.
57. Dubick MA, Williams C, Elgjo GI, Kramer GC: High-dose vitamin C infusion reduces fluid requirements in the resuscitation of burn-injured sheep. *Shock* 2005; 24: 139–144.
58. Zhang MJ, Zhang GL, Yuan WB et al.: Treatment of abdominal compartment syndrome in severe acute pancreatitis patients with traditional Chinese medicine. *World J Gastroenterol* 2008; 14: 3574–3578.
59. Lin WQ, Zhao YF: Creatural experiment of pharmacology study of Dachenqi Dococction. *Zhongyi Yanjiu* 2003; 16: 51–54.
60. Son BX: The progress of molecular experimental study of Dachenqi Dococction. *Guangmin Zhongyi* 1995; 1: 38–39.
61. Qing YJ, Lin F: The treatment of severe acute pancreatitis with TCM-wm therapy (30 cases). *Shiyong Zhenduan Yu Zhiliao Zazhi* 2006; 20: 838–839.

**Adres do korespondencji:**

Bart L. De Keulenaer  
Fremantle Hospital  
Intensive Care Unit  
1 Alma Street  
6160 Fremantle, WA, Australia  
e-mail: bdekeul@hotmail.com

Otrzymano: 18.08.2014 r.  
Zaakceptowano: 31.10.2014 r.